HARDI dMRI IMAGING OF CERVICAL SPINAL CORD

Jakub Zimolka[1,*], Zuzana Piskořová[1], Alena Svátková[2,3], Petr Bednařík[2,3], Tomáš Horák[2], Pavel Hok[4]

[1] DBME FEEC BUT, Brno, CZE; [2] CEITEC MU, Brno, CZE; [3] CMRR UMN, Minneapolis, USA; [4] UP Olomouc, CZE
[*] Master Degree Programme (2); E-mail: xzimol00@stud.feec.vutbr.cz

Supervised by: Josef Bednařík[2], Petr Hluštík[4], Christophe Lenglet[3] and René Labounek[1,4,#]

[#] E-mail: labounek@phd.feec.vutbr.cz, rene.labounek@upol.cz

Abstract: Our work established an automatic pipeline of cervical spinal cord high angular resolution diffusion imaging (HARDI) data. Our pipeline that projects the diffusion results into high-resolution anatomical space utilizes Spinal Cord Toolbox (SCT), FSL libraries, in-house developed scripts and TORQUE-based batch system for grid computational engines. As one of the first, we are investigating multiple-direction models for human in-vivo spinal cord HARDI dMRI data. The visually inspected preliminary results indicate that significant 2nd directions are observable as expected based on previously presented mainly animal models. Our work provides an essential clinical tool that will allow quantifying spinal cord and dorsal spinal roots alterations in various neurological diseases in vivo.

Keywords: diffusion MRI, dMRI, HARDI, Spinal Cord Toolbox, FSL, segmentation, anisotropic diffusion, diffusion tensor imaging, DTI, ball and stick model

1. INTRODUCTION

Diffusion-weighted MRI (dMRI) is a widely utilized imaging method to quantify white matter (WM) microstructure inside the brain or spinal cord, based on properties of 3D diffusion profile [1]. The 3D diffusion profile may be free (isotropic), or restricted (anisotropic) as often observed in the WM [2]. While diffusion tensor imaging (DTI) simplifies the 3D diffusion profile with single ellipsoid, it allows to track major anatomical WM pathways and evaluate its 3D anisotropic character [1]. In spinal cord, particularly, the DTI has appropriate ability to visualize axon fiber bundles oriented in the axial (main) direction, however, it could not visualize axon bundles aligned in the other (second, minor) e.g. medio-lateral direction. HARDI data [3] from cervical spinal cord, which enable to model more diffusion directions per single voxel (e.g. with ball and stick model [4] or with Q-ball imaging [5]), were acquired to overcome ambiguity of previously-utilized DTI techniques.

2. METHODS

2.1. MR IMAGING

MR imaging of the cervical spine was performed at 3T (Siemens Prisma MR) using 64 channel head and 32 channel neck coils. We have acquired sagittal and transversal T2-weighted anatomical images and transversal T2*-weighted HARDI dMRI datasets for 26 healthy volunteers (13 women, age 24.2 ± 1.7 years, weight 74.4 ± 14.1 kg, height 174.8 ± 7.6 cm) who participated in this study.

Sagittal T2-weighted images: spin-echo sequence with repetition time (TR)/echo time (TE): 8640/98 ms, 4 averages, matrix: 896×896, 30 contiguous 1,3 mm sections, field of view (FOV): 250×250 mm^2, voxel size: 0,28×0,28×1,3 mm^3.

Transversal T2-weighted images: gradient recalled sequence with TR/TE: 556/17 ms, 2 averages, matrix 512×512, 30 contiguous 2,5 mm sections, FOV: 180×180 mm^2, voxel size: 0,35×0,35×2,5 mm^3.

ZOOMit HARDI dMRI dataset: TR/TE 4500/73 ms, matrix 68×200×23, voxel size: 0,65×0,65×3 mm^3 (after interpolation in Fourier space), FOV = 44×129 mm^2. Scans with reverse phase encoding (anterior-posterior (AP) and posterior-anterior (PA)) were acquired. PA acquisition consisted only five b0 images, i.e. b=0 mms^{-2}. For AP acquisition: 63 diffusion weighted (42 directions with b=1000 mms^{-2} and 21 with b=550 mms^{-2}) and 7 un-weighted (b0) scans were collected.

2.2. DATA ANALYSIS

Preprocessing step consists of anatomical image fusion, spinal cord segmentation, dMRI data preprocessing (motion correction, distortion correction) and co-registration of anatomical and diffusion images. Anatomical T2-weighted scans (sagittal and axial) provide an optimal resolution in different planes. First, spinal cord was segmented from the T2-weighted sagittal image based on elliptical Hough transformation with following smoothing and post-processing as implemented in [6]. To achieve the best results, high-resolution fused image was estimated after affine multimodal registration [7] with weighted non-linear additive fusion (different weights inside - 90 % trans. intensity: 10 % sag. intensity - and outside of the spinal cord - 50/50 %). Then, the final spinal cord segmentation was made from the fused anatomical image [6]. Diffusion MRI data preprocessing consist of distortion (susceptibility) artifact removal, motion and eddy current correction realized by libraries `topup` [8] and `eddy` [9]. The mean b0 image was calculated from corrected dMRI data and co-registered to the anatomical fused image utilizing the two-step affine registration using the earlier spinal cord segmentation as the input and the mutual information as the final similarity criterion [7]. The pre-processed dMRI data were separately fitted into tensor [1] and ball and stick model [4]. The diffusion space results were transformed into fused anatomical space for visual quality evaluations.

3. RESULTS

Figure 1a and 1b demonstrate T2-weighted anatomical fused high resolution (high-res) image. The visual inspection of anatomical image fusion indicates that it is working properly on all subjects. Gray matter (GM) and WM of the spinal cord are clearly distinguishable on the axial plane. Figure 1b represents the magnification of their corresponding Figure 1a. In comparison, Figure 1d shows the raw T2-weighted transversal image that does not allow to depict such subtle anatomical details as fused images. Figure 1c shows the binary mask of the spinal cord segmentation, denoted in red. There is a small part of the spinal cord where the segmentation overflows and we get false positive segmentation results. Fractional anisotropy (FA) [2] in the anatomical space (Figure 1e) and diffusion

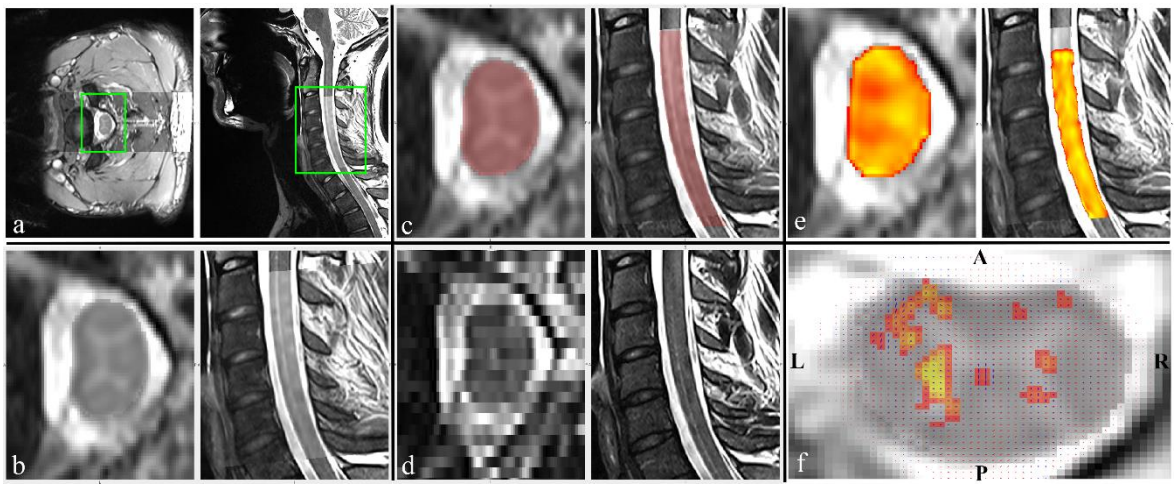

Figure 1: Single subject results: **a** represents T2-weighted anatomical fused high-res image, **b** is zoomed **a**, **c** shows spinal cord segmentation, **d** is T2-weighted sagittal image, **e** represents T2-weighted anatomical fused high-res image with ZOOMit HARDI dMRI FA map in anatomical space (red=0.3; yellow=0.9) and **f** is ZOOMit HARDI dMRI data with ball and stick model with 1st and 2nd fiber direction registered on T2 fused anatomical high-res image with partial volumes of 2nd fiber directions (red=0.05; yellow=0.28), which represents the percentile of the whole dMRI signal.

vector estimation on T2-weighted fused high-res image (Figure 1f) are provided. Beside DTI, we additionally utilized multi-direction single-voxel estimations and detected significant 2nd fiber directions with partial volumes of dMRI signal *f2* <0.1-0.3> in areas of GM with fiber crossing and in areas of spinal nerve roots origin (Figure 1f).

4. DISCUSSION

Our work established an automatic processing pipeline of unique in-vivo human cervical spinal cord HARDI dMRI data. We achieved anatomical image fusion as well as automatic segmentation of the spinal cord [6]. However, the visual control of potential false positive segmentation outcomes with respect to low FA values is still needed (Figure 1c). As expected, FA maps show visible decreases in areas of GM, and DTI mainly visualize only bundles oriented in axial direction. Localization of 2nd fiber bundles and their significant partial volume in dMRI signal demonstrate that HARDI imaging has potential in future methodological and clinical research. We are currently fine-tuning image normalization to the template space and WM/GM segmentation. After that, mathematical and statistical evaluations can be done from distinct areas of spinal cord over different groups (e.g. men vs women, or later patients vs controls). Current spinal cord segmentation [6] fails in root segmentation. While they are observable in fused anatomical images, this step should be improved in the future. Despite current limitations and simultaneous concurrent investigations [10], our project unquestionably represents one of the first studies utilizing HARDI on human spinal cords in vivo. Our work has the potential to expand our understanding of microstructural deficits in various neurological conditions affecting spinal cord.

ACKNOWLEDGEMENT

We would like to express many thanks to Julien Cohen-Adad from Polytechnique Montréal in Canada for his help and insightful advice with optimal Spinal Cord Toolbox settings.
We acknowledge the core facility Multimodal and Functional Imaging Laboratory, institution Masaryk University, CEITEC supported by the MEYS CR (LM2015062 Czech-BioImaging); special thanks to Lubomír Vojtíšek, Veronika Fabíková and Petr Kudlička.
Computational resources were supplied by the MEYS CR under the Projects CESNET (Project No. LM2015042) and CERIT-Scientific Cloud (Project No. LM2015085).

REFERENCES

[1] BASSER, P. J., et al. Estimation of the Effective Self-Diffusion Tensor from the NMR Spin Echo. J. Magn. Reson., Series B. 1994, 103, 247-54.
[2] MORI, S., et al. Introduction to diffusion tensor imaging and higher order models. Second edition. Amsterdam: Elsevier, 2014. ISBN 978-0-12-398398-5.
[3] TUCH, D., et al. High angular resolution diffusion imaging reveals intravoxel white matter fiber heterogeneity. Magn. Reson. Med. 2002, 48(4), 577-82.
[4] BEHRENS, T.E.J., et al. Characterization and propagation of uncertainty in diffusion-weighted MR imaging. Magn. Reson. Med. 2003, 50(5), 1077-88.
[5] TUCH, D. Q-ball imaging. Magn. Reson. Med. 2004, 52(6), 1358-72.
[6] DE LEENER, B., et al. Segmentation of the human spinal cord. MAGMA. 2016, 29, 125-53.
[7] DE LEENER, B., et al. SCT: Spinal Cord Toolbox, an open-source software for processing spinal cord MRI data, NeuroImage, 2017, 145, 24-43.
[8] JESPER, L.R., et al. How to correct susceptibility distortions in spin-echo echo-planar images: application to diffusion tensor imaging, NeuroImage, 2003, 20(2), 870-88.
[9] JESPER, L. R., et al. An integrated approach to correction for off-resonance effects and subject movement in diffusion MR imaging. NeuroImage, 2016, 1063-78.
[10] COHEN-ADAD, J., et al. Demyelination and degeneration in the injured human spinal cord detected with diffusion and magnetization transfer MRI. NeuroImage. 2011, 55(3), 1024-33.